Arthroscopic Repair of Massive Rotator Cuff Tears With Stage 3 and 4 Fatty Degeneration

Stephen S. Burkhart, M.D., Johannes R. H. Barth, M.D., David P. Richards, M.D., Michael B. Zlatkin, M.D., and Mitchell Larsen, M.D.

Purpose: The purpose of this study was to assess the functional results of arthroscopic repair of massive rotator cuff tears in patients who had stage 3 and 4 fatty degeneration of the rotator cuff musculature, according to the Goutallier scale. **Methods:** From January 1997 to December 2001, 22 patients with massive rotator cuff tears and Goutallier stage 3 or 4 fatty degeneration of the infraspinatus, with a mean age of 66.5 ± 9.26 years, underwent arthroscopic rotator cuff repair and were available for follow-up. The average tear size was 4.8 ± 0.85 cm in medial-to-lateral width and 6.2 ± 1.53 cm in anterior-to-posterior length, with an approximate tear size area of 30.0 ± 10.0 sq cm, and involved 2 tendons (supraspinatus and infraspinatus) or 3 tendons (supraspinatus, infraspinatus, and subscapularis) in each case. The mean time from surgery to follow-up was 39.3 months (range, 24-60 months). In addition to comparison of preoperative and postoperative range of motion, strength and University of California, Los Angeles (UCLA) score, outcomes were also assessed with the Constant score. **Results:** The increase of mean active forward elevation was 53.7° (preoperative: 103.2° and postoperatively: 156.9°). The gain of mean active external rotation was 19.1° (preoperative: 35.7° and postoperative: 54.8°). The gain of mean external rotation power was 1.9 (preoperative: 2.3 and postoperative: 4.2). The improvement in the UCLA score was 17.2 points (preoperative: 12.3 and postoperative: 29.5). The mean postoperative Constant score was 74.8/100, and the weighted postoperative Constant score was 88.5/100. In 5 patients with fatty degeneration greater than 75% (advanced stage 4), results were less dramatically improved than in 17 patients with fatty degeneration of 50% to 75%, all of whom exhibited clinical improvement. However, clinical improvement was achieved even in 2 of 5 patients with advanced stage 4 involvement. **Conclusions:** Arthroscopic rotator cuff repair in patients with grade 3 or 4 fatty degeneration (≥50%) can provide significant functional improvement. Those with 50% to 75% fatty degeneration showed a much greater degree of improvement (with all 17 cases exhibiting beneficial postoperative increases in their UCLA scores ranging from 12 to 26 points) than those with >75% fatty degeneration (with only 2 of 5 cases showing an increase of 10 or more points in their UCLA scores). However, clinical improvement was observed in 86.4% of cases that would have been classified as likely to fail by the Goutallier criteria. **Level of Evidence:** Level IV, therapeutic case series. **Key Words:** Rotator cuff—Rotator cuff tear—Fatty degeneration—Fatty infiltration—Tendon healing.

Fatty degeneration of the rotator cuff muscles, as determined on magnetic resonance imaging (MRI) or computed tomography (CT) scan, is frequently invoked as a contraindication, or at least a relative contraindication, to rotator cuff repair.[1-4] This treatment philosophy has evolved primarily because of the work of Goutallier et al.,[5,6] who devised a grading system for fatty degeneration (Table 1). They reported that patients with stage 3 (50%) and stage 4 (greater than 50%) fatty degeneration of the infraspinatus did not improve after rotator cuff repair. In contrast, over the past several years, our experience has been different in that most of our patients with arthroscopic repair of massive cuff tears with stage 3

From the Department of Orthopaedic Surgery, University of Texas Health Science Center at San Antonio (S.S.B., M.L.), San Antonio, Texas, U.S.A.; The San Antonio Orthopaedic Group (S.S.B., J.R.H.B.), San Antonio, Texas, U.S.A.; Institute for Bone and Joint Disorders (D.P.R.), Phoenix, Arizona, U.S.A.; Department of Radiology, University of Miami School of Medicine (M.B.Z.), Miami, Florida, U.S.A.; and National Musculoskeletal Imaging (M.B.Z.), Weston, Florida, U.S.A.

S.S.B. is a consultant for Arthrex, Naples, Florida. The other authors report no conflict of interest.

Address correspondence and reprint requests to Stephen S. Burkhart, M.D., 150 E. Sonterrra Blvd., Suite 300, San Antonio, TX 78258. E-mail: ssburkhart@msn.com

0749-8063/07/2304-4558$32.00/0
doi:10.1016/j.arthro.2006.12.012

TABLE 1. *Goutallier Grading System of Fatty Degeneration of Muscle*

Stage	Findings (MRI/CT)
Stage 0	Normal muscle; no fatty streaking
Stage 1	Occasional fatty streaking
Stage 2	Fat <50% of cross-sectional area (fat < muscle)
Stage 3	Fat = 50% of cross-sectional area (fat = muscle)
Stage 4	Fat >50% of cross-sectional area (fat > muscle)

and 4 fatty degeneration have been significantly improved. The purpose of this study was 3-fold: to retrospectively study our results for this category of patients, to analyze potential causes for the difference in outcomes between our patients and those of Goutallier et al.[5,6] and to determine whether fatty degeneration of equal to or greater than 50% (stage 3 and 4) should be a contraindication to arthroscopic rotator cuff repair. Based on our experience, we hypothesized that patients with stage 3 and 4 fatty degeneration of the infraspinatus muscle belly on MRI would experience significant gains in function after arthroscopic rotator cuff repair.

METHODS

During the period from January 1997 to December 2001, the senior author (S.S.B.) performed arthroscopic repair of massive rotator cuff tears in 203 patients. One hundred seven charts had complete databases that included a detailed clinical examination and preoperative MRI. The fatty degeneration staging, according to the Goutallier scale (Table 1), was performed by a single musculoskeletal radiologist (M.B.Z.). Cases identified as having stage 3 (=50%) or 4 (>50%) fatty degeneration were selected for analysis. Cases were grouped into 1 of 2 categories: those with 50% to 75% fatty degeneration (group A) (Fig 1) and those with >75% fatty degeneration (group B) (Fig 2). Means and standard deviations were calculated for measures of interest for all selected cases as well as the groups and unpaired Student *t* tests or Mann-Whitney *U* tests (as appropriate) were performed for group comparisons.

Twenty-two patients who had massive rotator cuff tears (i.e., tears involving 2 or 3 tendons according to Gerber's definition of massive tear[1] in addition to having a diameter greater than 5 cm according to Cofield's definition[7]) were found to have stage 3 or 4 fatty degeneration of ≥50% of the infraspinatus. Five

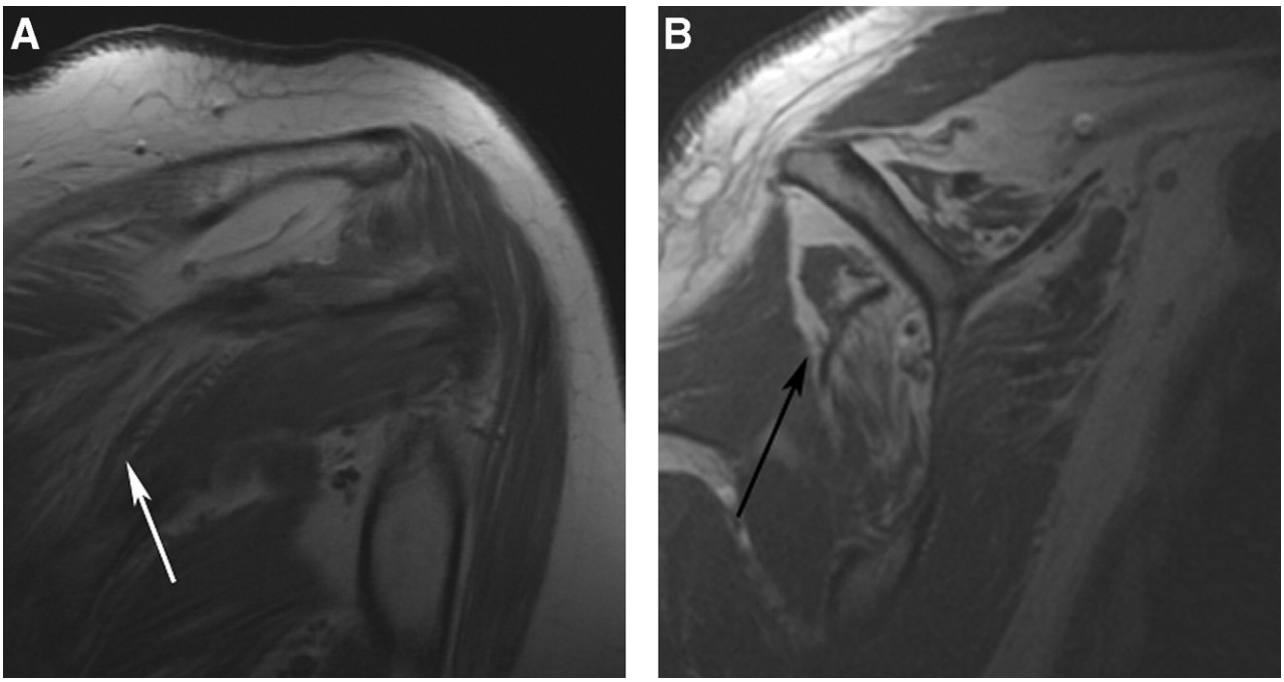

FIGURE 1. (A) Coronal oblique MRI section of a group A patient, TR/TE 2500/18. Fatty degeneration of the infraspinatus muscle of between 50% and 75% is identified (arrow). (B) Sagittal oblique MRI section of a group A patient, TR/TE 2500/18. Fatty degeneration of the infraspinatus muscle of between 50% and 75% is identified (arrow).

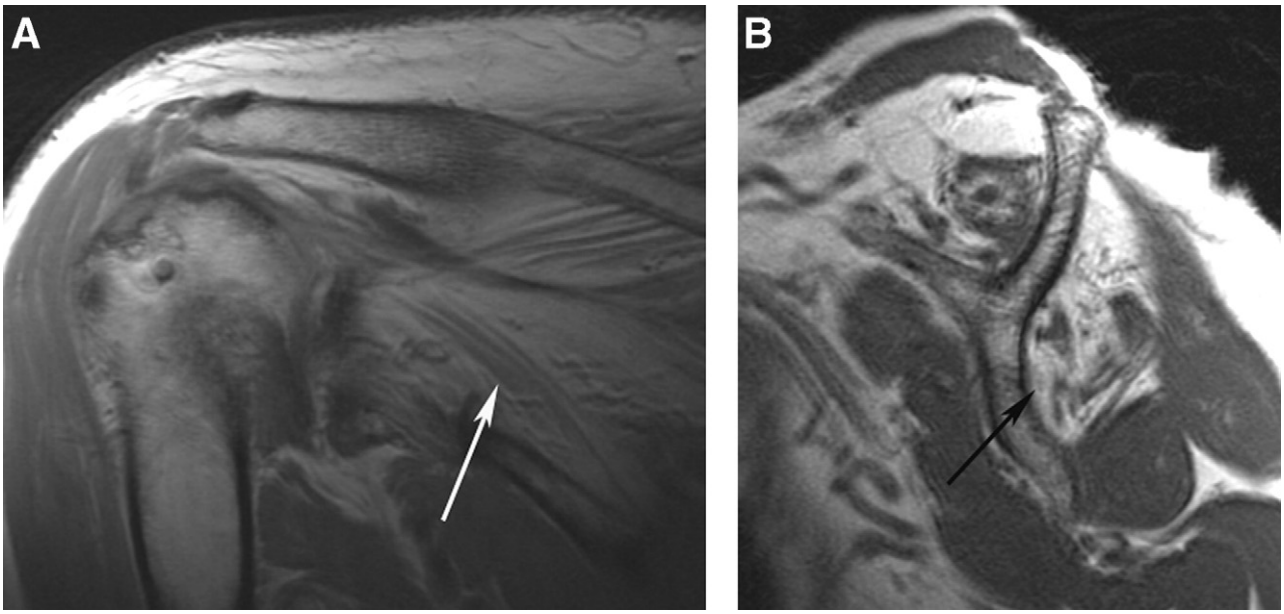

FIGURE 2. (A) Coronal oblique MRI section of a group B patient, TR/TE 2500/18. Greater than 75% fatty degeneration of the infraspinatus muscle is identified (arrow). (B) Sagittal oblique MRI section of a group B patient, TR/TE 700/14. Greater than 75% fatty degeneration of the infraspinatus muscle is identified (arrow).

of these 22 patients had more than 75% fatty degeneration of the infraspinatus. Nine of the shoulders had tears that involved the subscapularis. Tear size was measured arthroscopically with a calibrated measuring device to obtain medial-to-lateral and anterior-to-posterior dimensions of the tear. The average medial-to-lateral width of the tears was 4.8 ± 0.85 cm, the average anterior-to-posterior length was 6.2 ± 1.53 cm, and the average tear size area was 30.0 ± 10.00 sq cm. The mean age of the patients was 66.5 ± 9.26 years. Eighteen right and 4 left shoulders comprised the study group. There were 14 male patients and 8 female patients.

The preoperative mean active forward elevation was 103.2° ± 46.3°, and the active external rotation was 35.7° ± 23.9°. The preoperative University of California, Los Angeles (UCLA) score was 12.3 ± 3.1. The mean external rotation strength was 2.3 ± 0.7. Strength was assessed on a scale of 0 to 5, where 0 = no muscle function, 1 = muscle contraction is visible but not efficient, 2 = muscle contraction is possible but cannot overcome gravity, 3 = muscle contraction is barely possible against gravity, 4 = strength is decreased on resisted movement, and 5 = muscle strength is normal.

In group A, we had 17 patients, aged 66.5 ± 9.4 (12 men and 5 women). The mean preoperative active forward elevation was 103.5° ± 34.3°, mean active external rotation was 35.9° ± 24.2°, mean external rotation strength was 2.2 ± 0.8, and mean preoperative UCLA score was 12.4 ± 3.4.

In group B, we had 5 patients, aged 66.2 ± 9.9 years (2 men and 3 women). The mean preoperative active forward elevation was 102.0° ± 81.1°, mean active external rotation was 35.0° ± 25.5°, mean external rotation strength was 2.4 ± 0.5, and mean preoperative UCLA score was 12.2 ± 2.5. No significant differences between groups were observed for preoperative measures ($P > .50$).

All 22 patients underwent an arthroscopic rotator cuff repair, including 2 revisions. In each shoulder, the tear pattern was arthroscopically assessed by means of a tendon grasper, and the tear was repaired based on the tear pattern. U-shaped and L-shaped tears were repaired with a combination of side-to-side sutures and tendon-to-bone repair with suture anchors, whereas crescent-shaped tears were repaired directly to bone with suture anchors. In each of these 22 shoulders, a single row of suture anchors was used. The details of the technique have been previously described.[7-9] Postoperatively, patients were immobilized in a sling for 6 weeks. During that time, passive external rotation was initiated except in those shoulders that had a subscapularis repair. Patients with a subscapularis repair did not begin passive external rotation until 6 weeks postoperatively. All patients

TABLE 2. *Modified UCLA Scoring System*

Category	Points
Pain	
Present all of the time and unbearable, strong medication Frequently	1
Present all of the time but bearable, strong medication Occasionally	2
None or little at rest, present during light activities; salicylates Frequently	4
Present during heavy or particular activities only, salicylates Occasionally	6
Occasional and slight	8
None	10
Function	
Unable to use limb	1
Only light activities possible	2
Able to do light housework or most of activities of daily living	4
Most housework, shopping, and driving possible; able to do hair and dress and undress, including fastening brassiere	6
Slight restrictions only, able to work above shoulder level	8
Normal activities	10
Active forward flexion	
≥150°	5
120°-150°	4
90°-120°	3
45°-90°	2
30°-45°	1
<30°	0
Strength of resisted external rotation (manual testing)	
Grade 5 (normal)	5
Grade 4 (good)	4
Grade 3 (fair)	3
Grade 2 (poor)	2
Grade 1 (muscle contraction)	1
Grade 0 (nothing)	0
Satisfaction of the patient	
Satisfied and better	5
Not satisfied and worse	0

discontinued their slings and began overhead stretching exercises at 6 weeks postoperatively. Strengthening with Theraband tubing (The Hygenic Corporation, Akron, OH) was begun at 3 months postoperatively. In addition to the cuff repair, 19 patients had a subacromial decompression, 4 patients had an excision of the distal clavicle, 4 patients had a biceps debridement, 3 patients had a biceps tenodesis, 1 patient had a biceps tenotomy, and 3 patients had a SLAP lesion repair. The mean time from rotator cuff repair to follow-up was 39.3 months (range, 24-60 months).

At follow-up, assessment of range of motion for abduction, forward elevation, and external rotation (arm at the side) was performed. A grading of the strength in forward elevation, external rotation, and internal rotation was done. Outcomes were assessed according to the Constant[10] and modified UCLA (Table 2) scores.[11] All follow-up examinations were performed by a single examiner (J.R.H.B.) who had not performed the surgery.

RESULTS

At the time of follow-up, the following data were obtained.

Range of Motion

Mean active abduction was 156.0° ± 30.5°, mean active forward elevation was 156.9° ± 32.7° (gain, 53.7°), and mean active external rotation was 54.8° ± 19.8° (gain, 19.1°) (Figs 3 and 4). For group A, mean active abduction was 164.2° ± 17.6°, mean active forward elevation was 165.9° ± 17.2° (gain, 62.4°), and mean active external rotation was 60.9° ± 16.5° (gain, 25.0°). For group B, mean active abduction was 128.0° ± 48.7°, mean active forward elevation was 126.0° ± 53.7° (gain, 24.0°), and mean active external rotation was 34.2° ± 16.4° (loss, 0.8°). The postoperative mean active external rotation ($P < .010$) and mean change in active external rotation ($P < .020$) were both significantly greater for group A. Means for active abduction ($P > .15$) and active forward elevation ($P > .10$) were not significantly different.

Strength

Mean postoperative forward elevation strength was 4.0 ± 1.09 (gain, 1.5), mean external rotation strength

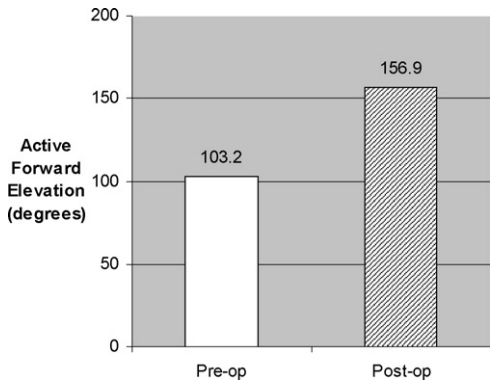

FIGURE 3. Comparison of preoperative and postoperative active forward elevation.

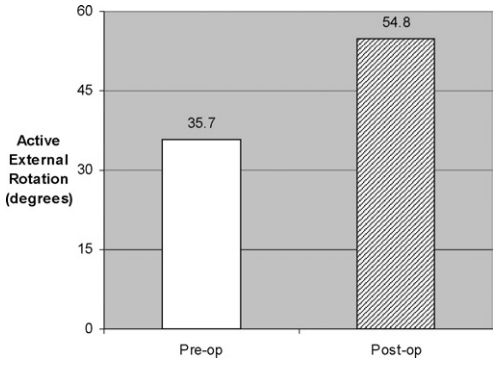

Figure 4. Comparison of preoperative and postoperative active external rotation.

was 4.2 ± 1.02 (gain, 1.9), and mean internal rotation strength was 4.3 ± 1.0 (Fig 5). For group A, mean forward elevation strength was 4.3 ± 0.8, mean external rotation strength was 4.5 ± 0.7 (gain, 2.3), and mean internal rotation strength was 4.5 ± 0.6. For group B, mean forward elevation strength was 2.8 ± 1.3, mean external rotation strength was 3.4 ± 1.5 (gain, 1.0), and mean internal rotation strength was 3.4 ± 1.5. Mean postoperative forward elevation strength was significantly greater for group A than for group B ($P < .005$). No significant group differences were observed for external rotation strength ($P > .15$) and internal rotation strength ($P > .15$).

Subjective Scores

The mean postoperative UCLA score was 29.5 ± 5.9, with a gain of 17.2 points. Eight patients had an excellent result (36.4%), 7 patients had a good result (31.8%), 4 patients had a fair result (18.2%), and 3 of them had poor results (13.6%) (Fig 6). For group A, the mean postoperative UCLA score was 31.5 ± 3.7, with an average gain of 19.1 points. Seven patients had an excellent result (41.2%), 7 patients had a good result (41.2%), 3 patients had a fair result (17.6%), and none of them had a poor result. For group B, the mean postoperative UCLA score was 22.6 ± 7.4, with a gain of 10.4 points. The mean postoperative UCLA score and mean increase in UCLA score were both significantly greater for group A ($P < .005$). One patient had an excellent result (20%), 1 patient had a fair result (20%), and 3 of them had poor results (60%). All the poor results were in group B.

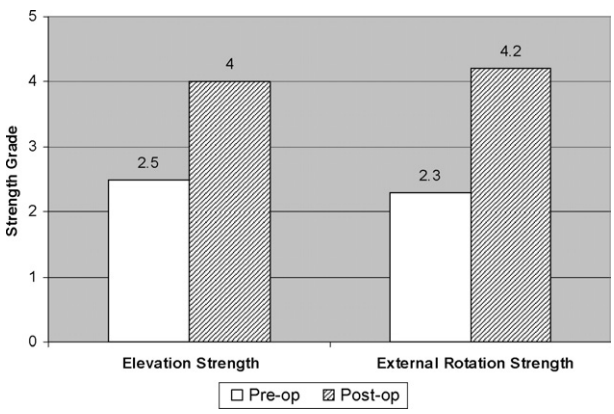

Figure 5. Comparison of preoperative and postoperative strength.

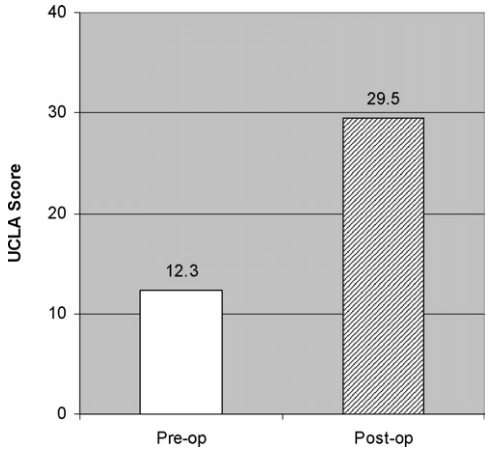

Figure 6. Comparison of preoperative and postoperative UCLA scores.

Objective Scores

Mean post-op Constant score was 74.8 ± 17.3 (out of 100) and weighted Constant score (adjusted to age and gender) was 88.5/100. For group A, mean post-op Constant score was 80.0 ± 11.7 and weighted Constant score was 94.8/100. For group B, mean post-op Constant score was 56.8 ± 22.6 and weighted Constant score was 67.2/100. Mean post-op Constant score ($P < .035$) and weighted Constant score ($P < .020$) were both significantly greater for group A.

DISCUSSION

Some authorities believe that rotator cuff repair in shoulders with 50% or greater fatty degeneration of the infraspinatus (as shown on MRI or CT scan) is doomed to failure.[2,12] This philosophy is based primarily on the work of Goutallier et al.,[5,6] who stated that patients with rotator cuff tears associated with

stage 3 (50%) or stage 4 (>50%) fatty degeneration of the infraspinatus did not improve after surgical repair. Although the original imaging studies were CT scans,[5,6] Gerber et al.[13] have shown that MRI and CT scans are equivalent in their ability to detect fatty degeneration of muscle. Additionally, MRI, because of improved contrast resolution, can better differentiate muscle from fibrous tissue and fat and has widely replaced CT scanning in the majority of centers for shoulder evaluation.[13]

Our experience in repairing rotator cuffs that have significant fatty degeneration has been quite different from that of Goutallier and of other authors who have embraced his indications.[2-4,13] The 22 patients in the current study would not have been surgical candidates by Goutallier criteria, and they would have been denied the opportunity for functional improvement because of the assumption that, based solely on their stage of fatty degeneration, they would have no chance of functional improvement with surgery. Yet, 19 of our 22 patients improved significantly after arthroscopic surgical repair of the rotator cuff. Active forward elevation improved an average of 53.7° (from 103.2° preoperatively to 156.9° postoperatively). Mean active external rotation improved 19.1° (from 35.7° preoperatively to 54.8° postoperatively). External rotation strength increased by 1.9 grades (preoperatively 2.3 and postoperatively 4.2). Strength of forward elevation increased by 1.5 grades (from a preoperative average of 2.5 to a postoperative average of 4.0).

We further subdivided our 22 stage 3 and 4 patients into 2 groups: those with 50% to 75% fatty degeneration and those with ≥75% fatty degeneration. All 17 stage 3 and 4 patients that were less severely involved (50% to 75% fatty degeneration) had clinical improvement. Active forward elevation in this group improved from 103.5° preoperatively to 165.9° postoperatively (gain, 62.4°), external rotation power improved by 2.3 grades, and UCLA score improved from 12.4 to 31.5, a gain of 19.1 points. In the worst group (5 patients with ≥75% fatty degeneration), clinical improvement was observed in 2 of 5 cases. Group B mean functional improvement was observed, with active forward elevation improving from 102° preoperatively to 126° postoperatively, external rotation power improving by 1.0 grade, and UCLA score improving from 12.2 to 22.6.

Why has our experience been so different from that of Goutallier and others?[2-6,13] There are only 2 possible explanations: either the patient selection criteria were different or the surgical techniques were so inherently different that they produced dramatically contrasting results in comparable patient populations.

Let's examine the first possibility, patient selection criteria. We were careful to include in this study only patients that had stage 3 and 4 fatty degeneration of the infraspinatus on preoperative MRI. The percentage fatty degeneration was determined by one of the authors (M.B.Z) with specialized training and expertise in musculoskeletal radiology. Previous studies have shown that MRI (as used by us) and CT scan (as used by Goutallier et al.[6]) are at minimum equally accurate for determining percentage of fatty degeneration.[13] Therefore, we believe that our patient population was comparable to that of Goutallier et al.

What about surgical technique? The most obvious difference between our technique and that of Goutallier et al.[5,6] was that our patients were all repaired arthroscopically by the senior author, whereas the patients in the Goutallier series were all repaired by open techniques. This difference in technique could result in a difference in scarring because certainly one would expect less scarring with an arthroscopic approach. But scarring alone should not cause such drastically different results.

What other surgical factors might have been important? First of all, the Goutallier patients all underwent medial to lateral repair.[5,6] If the apex of the tear would not reach its bone footprint on the greater tuberosity, then the supraspinatus muscle belly was completely elevated off its bone bed on the supraspinatus fossa of the scapula (Debeyre procedure[14]) and pulled laterally to achieve a medial to lateral repair to bone. This drastic global mobilization of the supraspinatus was performed in 40 of 63 patients.[5]

What are the problems with the Debeyre mobilization? First, the suprascapular nerve may be injured during this operation. Goutallier et al.[5,6] reported that such a nerve injury occurred in 5 of their patients. Second, the dissection involved in the Debeyre procedure causes such damage to the supraspinatus muscle that one must question whether it would ever function at all after this surgery. Finally, the fact that the Debeyre procedure was used in approximately two thirds of patients (so that a medial to lateral repair could be done) causes one to wonder whether U-shaped and L-shaped tear patterns were not appreciated and therefore not appropriately addressed.[14-16] If not, then it is likely that all U-shaped tears repaired without margin convergence would fail because of tension overload.[14-16] In view of the fact that our senior author's experience has shown a 42% incidence of U-shaped or L-shaped tears among all rotator cuff

tears,[16,17] we suspect that some of the reported failures could have resulted from lack of recognition (and therefore lack of appropriate repair) of U-shaped and L-shaped tears.

Another difference in technique between our series and that of Goutallier et al.[5,6] stems from our treatment of subscapularis tears. We were very careful to get a good arthrosopic view of the subscapularis footprint in each case, and we repaired all subscapularis tears, both complete and partial. On the other hand, Goutallier et al.[5,6] stated that they did not repair subscapularis tears even when they found them. We have previously shown the rather dramatic improvement that can be obtained in patients who lack overhead function because of large or massive rotator cuff tears that include the subscapularis. In such patients, repair of these tears can restore active overhead motion in 80% of the patients who do not have active overhead function preoperatively.[18] Furthermore, the subscapularis has been shown to function largely as a tenodesis so that fatty degeneration of its muscle belly may not be as important to function as in the other muscles of the rotator cuff.[18]

One may also speculate about the role of suprascapular nerve function in our patients. There is evidence that a massive retracted tear of the supraspinatus and infraspinatus produces a chronic traction injury of the suprascapular nerve and that rotator cuff repair improves suprascapular nerve function by reducing traction on the nerve.[19] Traction reduction on the suprascapular nerve could play a role in the functional improvement we observed after repair, and this effect would be independent of fatty degeneration.

So, why has a segment of the orthopaedic community come to embrace the practice of not repairing rotator cuff tears in the face of stage 3 and 4 fatty degeneration?[2-6,13] This practice has occurred largely as a consequence of studies in which the cuff was not repaired arthroscopically; tear patterns were not necessarily recognized and appropriately addressed, and a destructive global release of the supraspinatus muscle (Debeyre procedure) was done in over 60% of cases.[5,6]

In contrast, our patients had a thorough diagnostic arthroscopy, delineation of cuff tear patterns, and an anatomic arthroscopic repair of all tendons based on biomechanical principles, thereby creating a mechanically secure repair. Furthermore, every torn subscapularis tendon in our series was anatomically repaired to bone.

Our philosophy has been to re-establish as much force transmission as possible from the rotator cuff to the bone. The senior author (S.S.B.) has previously shown that the maximal force that can be generated by normal cuff muscles across a 4-cm diameter tear that involves 100% of the supraspinatus and 50% of the infraspinatus is 340 N. Assume that the muscles involved in such a tear have 50% fatty degeneration (stage 3); then, they can maximally generate a force of 170 N (38 lb).[20] Despite the muscles' reduced power because of fatty degeneration, this is still a significant force. If this potential rotator cuff muscle force could be directly transmitted to bone by means of surgical repair, one would expect that function would significantly improve. Even if a partial repair is all that could be accomplished, the patient would benefit not only from increased force transmission to bone but also from a significant decrease in shear forces at the margin of the tear, thereby decreasing the likelihood of extension of the tear.[21]

This discussion is not meant to detract from the work of Goutallier and his associates. However, we think that their conclusions have limited application to current indications for arthroscopic rotator cuff repair. Much of their work was initiated at a time when shoulder arthroscopy was not commonly performed. Once shoulder arthroscopy became commonplace, the importance of tear pattern recognition and surgical repair based on those tear patterns became more obvious. Furthermore, the importance of recognizing and repairing the torn subscapularis has been more fully shown.[18]

We have presented a series of 22 patients who, because they had at least 50% fatty degeneration of the infraspinatus on MRI, would have been denied the opportunity of functional improvement by surgical repair based on Goutallier's criteria. Yet, their functional improvement after arthroscopic rotator cuff repair was significant. We initially hypothesized that patients with stage 3 and 4 fatty degeneration of the infraspinatus muscle belly on MRI would experience significant gains in function after arthroscopic rotator cuff repair. Our hypothesis was borne out by the data from this study, which showed statistically significant improvement in 19 of our 22 patients. Based on our results, we believe that it is reasonable to proceed with arthroscopic rotator cuff repair in cases in which fatty degeneration is greater than 50% of the muscle belly. One must recognize, however, that the results in patients with >75% fatty degeneration are not nearly as good as those with 50% to 75% fatty degeneration.

CONCLUSION

Arthroscopic rotator cuff repair in patients with grade 3 or 4 fatty degeneration (≥50%) can provide significant functional improvement. Those with 50% to 75% fatty degeneration show a much greater degree of improvement than those with >75% fatty degeneration. However, clinical improvement was observed for some patients having >75% fatty degeneration and for all patients in the 50% to 75% group.

Acknowledgment: The authors thank John Schoolfield, M.S., for his assistance in performing the statistical analysis in this study.

REFERENCES

1. Gerber C. Massive rotator cuff tears. In: Iannotti JP, Williams GR, eds. *Disorders of the shoulder: Diagnosis and management*. Philadelphia: Lippincott Williams & Wilkins, 1999; 62-63.
2. Gerber C, Walch G. Massive rotator cuff tears. In: Norris TR, ed. *Orthopaedic knowledge update. Shoulder and elbow*. Rosemont, IL: American Academy of Orthopaedic Surgeons, 2002;191-196.
3. Warner JJ. Management of massive irreparable rotator cuff tears: The role of tendon transfer. *Instr Course Lect* 2001;50: 63-71.
4. Iannotti JP, Bernot MP, Kuhlman JR, Kelley MJ, Williams GR. Postoperative assessment of shoulder function: A prospective study of full-thickness rotator cuff tears. *J Shoulder Elbow Surg* 1996;5:449-457.
5. Goutallier D, Postel JM, Bernageau J, Lavau L, Voisin MC. Fatty muscle degeneration in cuff ruptures. Pre- and postoperative evaluation by CT scan. *Clin Orthop Relat Res* 1994; 304:78-83.
6. Goutallier D, Postel JM, Bernageau J, Lavau L, Voisin MC. Fatty infiltration of disrupted rotator cuff muscles. *Rev Rhum Engl Ed* 1995;62:415-422.
7. Cofield RH. Rotator cuff disease of the shoulder. *J Bone Joint Surg Am* 1985;67:974-979.
8. Burkhart SS. Current concepts: A stepwise approach to arthroscopic rotator cuff repair based on biomechanical principles. *Arthroscopy* 2000;16:82-90.
9. Lo IKY, Burkhart SS. Current concepts in arthroscopic rotator cuff repair. *Am J Sports Med* 2003;31:308-324.
10. Constant CR, Murley AH. A clinical method of functional assessment of the shoulder. *Clin Orthop Relat Res* 1987;214: 160-164.
11. Ellman H. Arthroscopic subacromial decompression: Analysis of one to three years results. *Arthroscopy* 1987;3:173-181.
12. Gerber C, Schneeberger AG, Perren SM, Nyffeler RW. Experimental rotator cuff repair. A preliminary study. *J Bone Joint Surg Am* 1999;81:1281-1290.
13. Gerber C, Fuchs B, Hodler J. The results of repair of massive tears of the rotator cuff. *J Bone Joint Surg Am* 2000;82:505-515.
14. Debeyre J, Patte D, Elmelik E. Repair of ruptures of the rotator cuff of the shoulder. *J Bone Joint Surg Br* 1965;47:36-42.
15. Burkhart SS, Athanasiou KA, Wirth MA. Margin convergence: A method of reducing strain in massive rotator cuff tears. *Arthroscopy* 1996;12:335-338.
16. Burkhart SS, Danaceau SM, Pearce CE Jr. Arthroscopic rotator cuff repair: Analysis of results by tear size and by repair technique-margin convergence versus direct tendon-to-bone repair. *Arthroscopy* 2001;17:905-912.
17. Burkhart SS. Arthroscopic treatment of massive rotator cuff tears. Clin Orthop Relat Res 2001;390:107-118.
18. Burkhart SS, Tehrany AM. Arthroscopic subscapularis tendon repair: Technique and preliminary results. *Arthroscopy* 2002; 18:454-463.
19. Albritton MJ, Graham RD, Richards RS 2nd, Basamania CJ. An anatomic study of the effects on the suprascapular nerve due to retraction of the supraspinatus muscle after a rotator cuff tear. *J Shoulder Elbow Surg* 2003;12:497-500.
20. Burkhart SS, Esch JC, Jolson RS. The rotator crescent and rotator cable: An anatomic description of the shoulder's "suspension bridge." *Arthroscopy* 1993;9:611-616.
21. Burkhart SS, Nottage WM, Ogilvie-Harris DJ, Kohn HS, Pachelli A. Partial repair of irreparable rotator cuff tears. *Arthroscopy* 1994;10:363-370.