Arthroscopic Latarjet Techniques: Graft and Fixation Positioning Assessed With 2-Dimensional Computed Tomography Is Not Equivalent With Standard Open Technique

Lionel Neyton, M.D., Johannes Barth, M.D., Geoffroy Nourissat, M.D., Pierre Métais, M.D., Pascal Boileau, M.D., Gilles Walch, M.D., and Laurent Lafosse, M.D.

Purpose: To analyze graft and fixation (screw and EndoButton) positioning after the arthroscopic Latarjet technique with 2-dimensional computed tomography (CT) and to compare it with the open technique. **Methods:** We performed a retrospective multicenter study (March 2013 to June 2014). The inclusion criteria included patients with recurrent anterior instability treated with the Latarjet procedure. The exclusion criterion was the absence of a postoperative CT scan. The positions of the hardware, the positions of the grafts in the axial and sagittal planes, and the dispersion of values (variability) were compared. **Results:** The study included 208 patients (79 treated with open technique, 87 treated with arthroscopic Latarjet technique with screw fixation [arthro-screw], and 42 treated with arthroscopic Latarjet technique with EndoButton fixation [arthro-EndoButton]). The angulation of the screws was different in the open group versus the arthro-screw group (superior, $10.3° \pm 0.7°$ vs $16.9° \pm 1.0°$ [$P < .001$]; inferior, $10.3° \pm 0.8°$ vs $15.7° \pm 0.9°$ [$P < .0001$]). The angulation of the EndoButtons was $5.7° \pm 0.5°$; this was different from that of open inferior screws ($P = .003$). In the axial plane (level of equator), the arthroscopic techniques resulted in lateral positions (arthro-screw, 1.5 ± 0.3 mm lateral [$P < .001$]; arthro-EndoButton, 0 ± 0.3 mm lateral [$P < .0001$]) versus the open technique (0.9 ± 0.2 mm medial). At the level of 25% of the glenoid height, the arthroscopic techniques resulted in lateral positions (arthro-screw, 0.3 ± 0.3 mm lateral [$P < .001$]); (arthro-EndoButton, 0.7 ± 0.3 mm lateral [$P < .0001$]) versus the open technique (1.0 ± 0.2 mm medial). Higher variability was observed in the arthro-screw group. In the sagittal plane, the arthro-screw technique resulted in higher positions ($55\% \pm 3\%$ of graft below equator) and the arthro-EndoButton technique resulted in lower positions ($82\% \pm 3\%$, $P < .0001$) versus the open technique ($71\% \pm 2\%$). Variability was not different. **Conclusions:** This study shows that the position of the fixation devices and position of the bone graft with the arthroscopic techniques are statistically significantly different from those with the open technique with 2-dimensional CT assessment. In the sagittal plane, the arthro-screw technique provides the highest positions, and the arthro-EndoButton technique, the lowest. Overall, the mean position of the bone block with the open Latarjet technique in the axial plane is slightly medial to the joint line, as recommended. Conversely, with the arthroscopic techniques, the bone grafts are more lateral with a slight overhang. The main differences are observed in the dispersion of the values (more extreme positions) with the arthro-screw technique, given the acknowledged limitations. Despite the statistical significance, the clinical significance of these differences is yet unknown. **Level of Evidence:** Level III, retrospective comparative study.

The concept developed by Latarjet is to act on the glenoid neck with the removal of the altered structures and to place the bone block here and nowhere else.[1] Subsequently, the position of the bone block is crucial. Historical reports on the procedure by Latarjet have shown that fixation of the bone graft was

From Ramsay Générale de Santé, Hôpital Privé Jean Mermoz (L.N., G.W.), Lyon; Centre Orthopédique Santy (L.N., G.W.), Lyon; Clinique des Cèdres (J.B.), Echirolles; Clinique Maussins-Nollet (G.N.), Paris; Hôpital Privé La Châtaigneraie - ELSAN (P.M.), Beaumont; CHU Nice—Hôpital Pasteur 2 (P.B.), Nice; and Clinique Générale Annecy (L.L.), Annecy, France.

The authors report the following potential conflict of interest or source of funding: L.N. receives support from Tornier Wright, Arthrex. P.B. receives support from Smith & Nephew, Wright. Imascap. Equity. G.W. receives support from Tornier Wright, Imascap. L.L. receives support from DePuy, Stryker, DePuy Mitek. Full ICMJE author disclosure forms are available for this article online, as supplementary material.

Paper previously presented at: Asia-Pacific Knee, Arthroscopy, and Sports Medicine Society Congress, Hong Kong, June 9—12, 2016.

Received September 27, 2017; accepted January 30, 2018.

Address correspondence to Lionel Neyton, M.D., Centre Orthopédique Santy Shoulder Unit, 24 Avenue Paul Santy, F-69008 Lyon, France. E-mail: neyton.lionel@orange.fr

0749-8063/17811/$36.00

https://doi.org/10.1016/j.arthro.2018.01.054

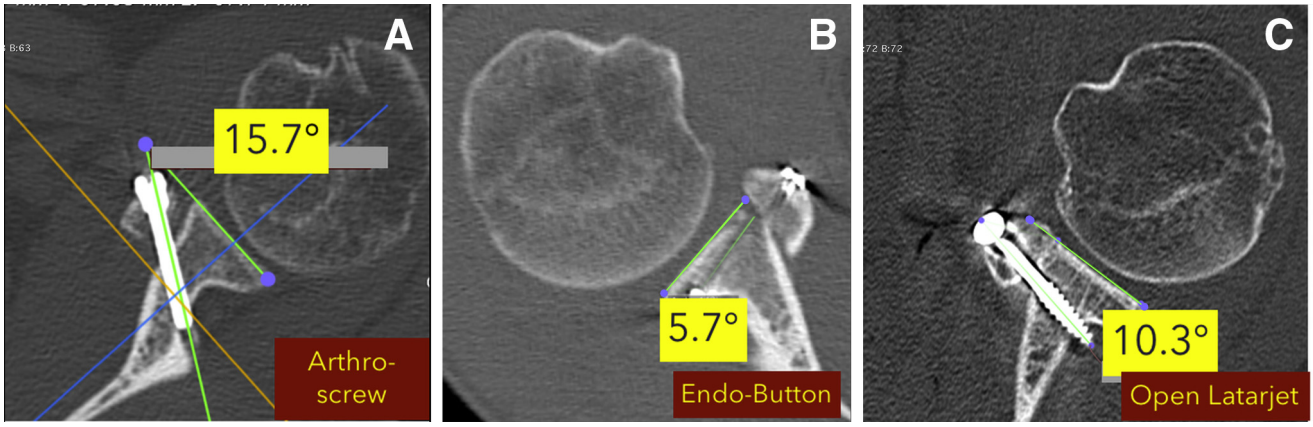

Fig 1. Angulation of fixation devices relative to joint line in axial plane. (A) Arthroscopic Latarjet technique with screw fixation (arthro-screw). (B) Arthroscopic Latarjet technique with EndoButton fixation (arthro-EndoButton). (C) Open Latarjet technique.

initially achieved with 1 screw that had to be strictly perpendicular to the anterior surface of the neck of the scapula, at the mid distance of the superior and inferior borders of the glenoid. In the axial plane, the bone block had to be a few millimeters medial to the joint line (subchondral bone) without any attempt to reconstruct the glenoid articular arc surface.[2,3] Walch[4] advocated avoiding any overhanging of the bone block with respect to the joint line because of potential secondary degenerative changes. Further studies confirmed the detrimental effect of too lateral placement of the bone block, and this was correlated with glenohumeral arthritis.[5,6] Thus, the position of the bone block in the axial plane is recommended to be flush with the joint line or slightly medial to it. However, excessive medial placement of the bone graft may be associated with failure of the stabilization of the joint.[7,8]

The assessment of the position of the bone graft is routinely performed with standard radiographs, but Clavert et al.[9] recently showed the low reliability of standard radiographs to precisely analyze coracoid graft positioning. In contrast, computed tomography (CT) scans seem to offer more reliable measurements of the position of the graft in the different planes.[10-12] One of the advantages promoted with the arthroscopic technique is the provision of different views of the graft, thus potentially allowing more accurate placement.[13] Our purpose was to analyze graft and fixation (screw and EndoButton [Smith & Nephew, Andover, MA]) positioning after the arthroscopic Latarjet technique with 2-dimensional CT and to compare it with the open technique. Our hypothesis was that the fixation device position and coracoid graft position would not be statistically significantly different with the arthroscopic techniques compared with the gold-standard open technique.

Methods

From March 2013 to June 2014, a multicenter retrospective study (approved by the ethical committee; CERC-VS-2016-02-1) was conducted in 9 centers. Three hundred ninety consecutive patients treated with the Latarjet procedure for recurrent anterior instability were included. For the purpose of this study, a CT scan evaluation of the operated shoulder was proposed for each patient early after the procedure (within the first 6 weeks postoperatively). We decided to use this maximum time frame to avoid any influence of bone remodeling of the graft that can occur.

The inclusion criteria were as follows: (1) patients operated on with the Latarjet procedure (open or arthroscopic technique) for recurrent anterior instability, (2) patients with or without previous open or arthroscopic Bankart stabilization procedures, and (3) patients with CT scan evaluations within the first 6 weeks postoperatively. The exclusion criterion was the absence of a postoperative CT scan. According to the surgical center and surgeon, patients were operated on with either an open Latarjet technique, arthroscopic Latarjet technique with screw fixation (arthro-screw), or arthroscopic Latarjet technique with EndoButton fixation (arthro-EndoButton).

Operative Technique

The open Latarjet technique was performed through a deltopectoral approach with subscapularis muscle horizontal splitting and fixation of the bone block to the anterior aspect of the neck of the glenoid with 2 screws. The screws were placed freehand.[14] According to the surgeon, either two malleolar AO 4.5-mm screws (Zimmer, Warsaw, IN) or two 4.5-mm low-profile partially threaded cannulated titanium screws (Arthrex, Naples, FL) were used. The arthro-screw technique was performed with mimicking of the open technique under arthroscopic control with fixation by 2 cannulated screws (DePuy Mitek, Raynham, MA), according to the technique described by Lafosse et al.[15,16] The arthro-EndoButton technique was performed under arthroscopic control with fixation of the

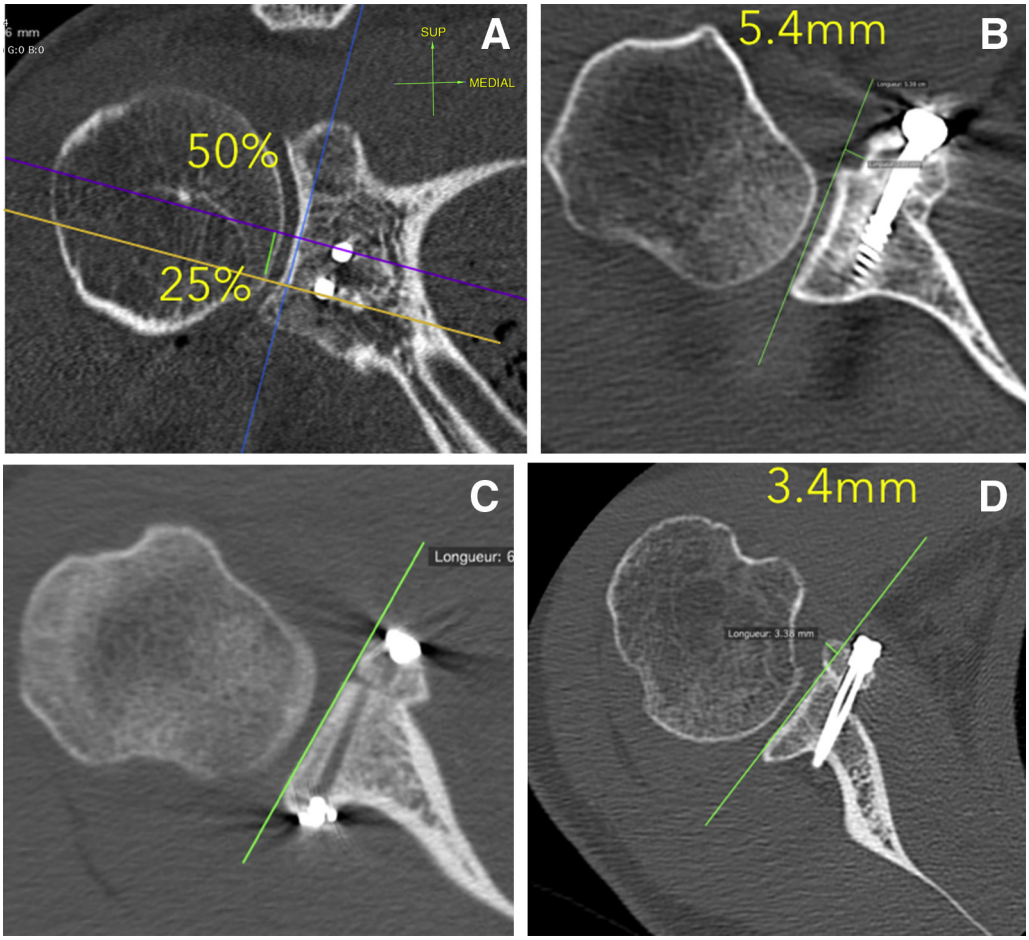

Fig 2. Position of bone block in axial plane (at level of 50% and 25% of glenoid height) measured at its most lateral aspect relative to joint line. (A) The 50% line (purple) and 25% line (yellow) of the glenoid height according to Barth et al.[11] (B) The bone block was considered medial if its most lateral aspect was 4 mm medial to the joint line or greater. (C) The bone block was considered flush if between +1 and −4 mm. (D) The bone block was considered lateral if greater than 1 mm lateral relative to the joint line. (SUP, superior.)

bone block thanks to a specific EndoButton device (Smith & Nephew), according to the technique described by Boileau et al.[17]

Two-dimensional CT Scan Evaluation

All examinations were recorded on a CD for further analysis by 2 different shoulder surgeons (L.N., J.B.) using OsiriX software (OsiriX Lite, version 7.0.1; Pixmeo, Geneva, Switzerland) and a specific standardized protocol.[11] The CT scan analysis protocol included evaluation of the coracoid graft positioning in the axial plane and in the sagittal plane.

Axial Plane. The surgeons measured the angulation of the screws (superior and inferior) in the open and arthro-screw groups and of the fixation device (tunnel in the glenoid) in the arthro-EndoButton group relative to the joint line. The joint line was defined as the line between the anterior and posterior aspects of the glenoid in the axial plane (Fig 1).

Analysis of the position of the bone block was performed relative to the joint line at the level of 50% and 25% (from the bottom of the glenoid) of the glenoid height (Fig 2). The bone block was considered medial if its most lateral aspect was 4 mm medial to the joint line or greater. It was considered flush if between +1 and −4 mm (positive numbers indicate lateral placement whereas negative numbers represent medial placement relative to the joint line). It was considered lateral if greater than 1 mm lateral relative to the joint line.

Sagittal Plane. The surgeons determined the position as the percentage of the bone block under the 50% line (equator) (Fig 3).

Statistical Analysis

Statistical analysis was performed using XLSTAT software (2015 release; Addinsoft). The distributions of the quantitative parameters in the different surgical technique groups were compared using the classic

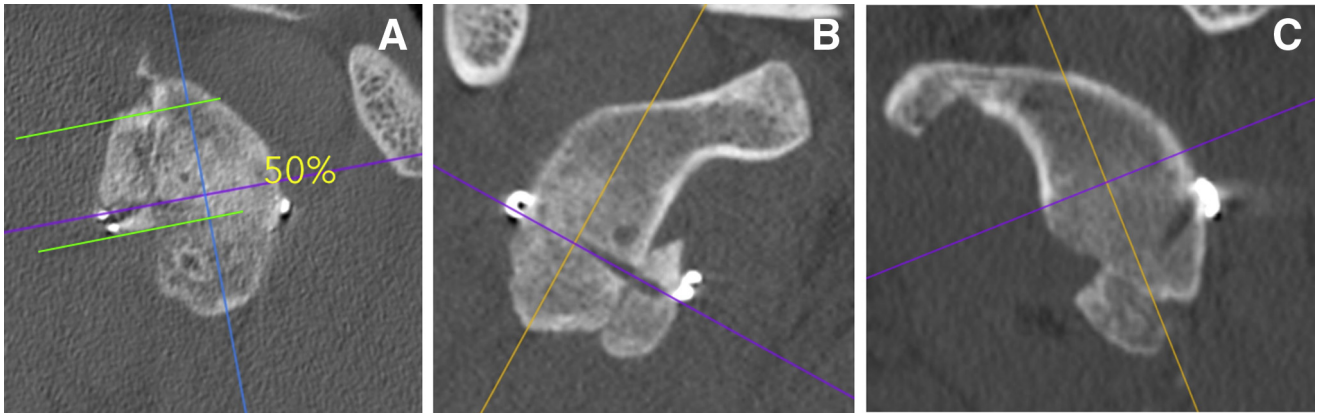

Fig 3. Position as percentage of bone block under 50% line (equator) in sagittal plane. (A) Example of a bone block in a high position with 10% of the graft below the equator. (B) Intermediate position with approximately 50% below the equator. (C) Low position with 100% under the level of the equator.

Mann-Whitney *U* test and Levene test of homogeneity of variance relative to the median and mean. The comparisons are presented with 95% confidence intervals (CIs). *P* values (2-sided probability) of less than .05 were considered statistically significant. Variabilities are presented by box plots displaying the median, quartiles, and minimum and maximum values of the distributions.

Results

Study Population

A total of 208 patients (53.3%) met the inclusion criteria.

Open Latarjet Group. Of the patients, 79 (38%) underwent the open Latarjet procedure in 2 different centers with 2 different surgeons (G.W., J.B.). One case was a revision procedure after an open Bankart procedure.

Arthro-screw Group. Of the patients, 87 (42%) underwent the arthroscopic Latarjet technique with screw fixation in 3 different centers with 3 different surgeons (G.N., L.L., P.M.). Six cases were revision procedures after arthroscopic Bankart procedures.

Arthro-EndoButton Group. Of the patients, 42 (20%) underwent the arthroscopic Latarjet technique with EndoButton fixation in 1 center with 1 surgeon (P.B.). Five cases were revision procedures after arthroscopic Bankart procedures. There were no differences between the 3 groups at inclusion except for dominant side operated on (Table 1).

Superior Screw Angulation Relative to Joint Line in Axial Plane

The mean angulation of the superior screw relative to the joint line was 10.3° (95% CI, 9°-11.7°) in the open Latarjet group and 16.9° (95% CI, 15°-18.8°) in the arthro-screw group ($P < .001$) (Table 2). The superior screw position was more variable (higher dispersion of values) in the arthro-screw group compared with the open Latarjet group ($P = .003$) (Fig 4A).

Inferior Screw or Fixation Device Angulation Relative to Joint Line in Axial Plane

The mean angulation of the inferior screw relative to the joint line was 10.3° (95% CI, 8.7°-12°) in the open Latarjet group, 15.7° (95% CI, 13.9°-17.4°) in the arthro-screw group, and 5.7° (95% CI, 4.7°-6.7°) in the arthro-EndoButton group (Table 3). The position of the inferior screw was significantly different between the open and arthro-screw groups ($P < .0001$). The position of the inferior screw in the open Latarjet group was different from that of the fixation device in the arthro-EndoButton group ($P = .003$).

Table 1. Baseline Demographic and Clinical Characteristics for Each Group

	Open Latarjet (n = 79)	Arthro-screw (n = 87)	Arthro-EndoButton (n = 42)	*P* Value
Sex	14 F and 65 M	17 F and 70 M	10 F and 32 M	.73
Dominant side operated on (yes or no), n	31 (39%)	51 (59%)	28 (67%)	.006
Sport practice (yes or no), n	70 (90%)	77 (89%)	35 (83%)	.65
Competition (yes or no), n	34 (44%)	46 (53%)	17 (40%)	.3
Age at first episode, mean ± SD, yr	23.1 ± 7.6	23.5 ± 8.4	26.6 ± 9.7	.09
Prior surgery (Bankart procedure), n	1 (1%)	6 (7%)	5 (12%)	.052
Age at surgery, mean ± SD, yr	28.1 ± 8.9	27.2 ± 9.3	29.6 ± 10.4	.4

Arthro-EndoButton, arthroscopic Latarjet technique with EndoButton fixation; Arthro-screw, arthroscopic Latarjet technique with screw fixation; F, female; M, male; SD, standard deviation.

Table 2. Superior Screw Angulation Relative to Joint Line in Axial Plane

	Open Latarjet (n = 79)	Arthro-screw (n = 87)
Mean ± SEM, °	10.3 ± 0.7	16.9 ± 1.0
Range, °	0-28.5	0-41.7
95% CI, °	9-11.7	15-18.8

Arthro-screw, arthroscopic Latarjet technique with screw fixation; CI, confidence interval; SEM, standard error of mean.

There was a statistically significant difference between the 2 arthroscopic techniques ($P < .0001$). The variability was the lowest in the arthro-EndoButton group (lowest dispersion of values) compared with the 2 other techniques ($P < .0001$). The variability was not different between the arthro-screw and open techniques ($P = .22$) (Fig 4B).

Position of Bone Block at Level of Line at 50% of Glenoid Height (Equator) in Axial Plane

The mean position of the bone block relative to the joint line at the level of 50% of the glenoid height was −0.9 mm (95% CI, −1.4 to +0.5 mm) in the open Latarjet group, +1.5 mm (95% CI, −0.9 to +2.1 mm) in the arthro-screw group, and 0 mm (95% CI, −0.6 to +0.6 mm) in the arthro-EndoButton group (Table 4). The position was significantly different between the open Latarjet and arthro-screw groups ($P < .0001$) and between the open Latarjet and arthro-EndoButton groups ($P < .0001$). There was no statistically significant difference between the 2 arthroscopic techniques.

The arthro-screw technique showed the highest variability of the position of the bone block in the axial plane at the level of the 50% line (higher dispersion of values) compared with the 2 other techniques (open technique, $P = .0003$; arthro-EndoButton technique, $P = .0006$). There was no difference between the arthro-EndoButton and open techniques ($P = .1$) (Fig 5A).

Position of Bone Block at Level of Line at 25% of Glenoid Height in Axial Plane

The mean position of the bone block relative to the joint line at the level of 25% of the glenoid height was −1.0 mm (95% CI, −7 to +3.8 mm) in the open Latarjet group, +0.3 mm (95% CI, −0.2 to +0.9 mm) in the arthro-screw group, and +0.7 mm (95% CI, −0.4 to +0.2 mm) in the arthro-EndoButton group (Table 5). The mean position was significantly different between the open Latarjet and arthro-screw groups ($P < .001$) and between the open Latarjet and arthro-EndoButton groups ($P < .001$). There was not a statistically significant difference between the 2 arthroscopic techniques ($P = .3$).

The variability of the position at the level of the 25% line was not different between the 2 arthroscopic techniques ($P = .12$). The variability was not different between the open technique and the arthro-EndoButton technique ($P = .42$). The variability of the arthro-screw technique was higher compared with the open technique ($P = .006$) (Fig 5B).

Position of Bone Block in Sagittal Plane Relative to Equator

In the sagittal plane, the mean position of the bone block below the equator was 71% (95% CI, 67.3%-74%) in the open Latarjet group, 55% (95% CI, 49%-61%) in the arthro-screw group (highest mean position), and 82% (95% CI, 76%-87%) in the arthro-EndoButton group (lowest mean position) (Table 6). The mean position in the sagittal plane with the open Latarjet technique was

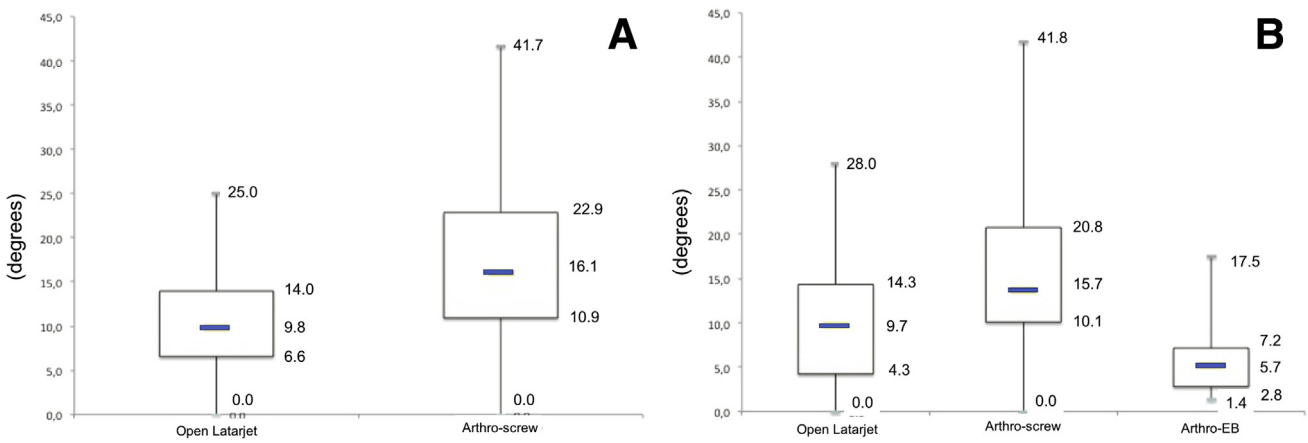

Fig 4. (A) Mean angulation and dispersion of values of superior screw in axial plane. (B) Mean angulation and dispersion of values of inferior screw or fixation device in axial plane. The box plots display the median, quartiles, and minimum and maximum values of the distributions. Positive values are indicative of lateral placement whereas negative values are indicative of medial placement relative to the joint line. (Arthro-EB, arthroscopic Latarjet technique with EndoButton fixation; Arthro-screw, arthroscopic Latarjet technique with screw fixation.)

Table 3. Inferior Screw or Fixation Device Angulation Relative to Joint Line in Axial Plane

	Open Latarjet (n = 79)	Arthro-screw (n = 87)	Arthro-EndoButton (n = 42)
Mean ± SEM, °	10.3 ± 0.8	15.7 ± 0.9	5.7 ± 0.5
Range, °	0-285	0-41.8	1.4-17.5
95% CI, °	8.7-12	13.9-17.4	4.6-6.7

Arthro-EndoButton, arthroscopic Latarjet technique with EndoButton fixation; Arthro-screw, arthroscopic Latarjet technique with screw fixation; CI, confidence interval; SEM, standard error of mean.

significantly different from that with the arthro-screw technique ($P < .001$) and the arthro-EndoButton technique ($P < .001$). The mean position in the sagittal plane was significantly different between the 2 arthroscopic techniques ($P < .001$). No statistically significant difference was found in the variability among the 3 techniques ($P = .2$) (Fig 6).

Discussion

We showed significant differences in the positions of the fixation devices and of the bone block depending on the surgical technique. The potential advantage promoted with the arthroscopic technique is the provision of different views of the graft, thus potentially allowing more accurate placement. We hypothesized that the positions of the fixation devices and of the coracoid graft would not be statistically significantly different with the 2 arthroscopic techniques compared with the open technique. Our hypothesis was not confirmed.

The superior and inferior screw positions in the axial plane were statistically significantly different between the arthro-screw technique and open technique, with a significantly more medial direction and less parallel orientation to the joint line with the arthroscopic technique. Latarjet[2] recommended that the orientation of the screw should be perpendicular to the anterior wall of the glenoid and parallel to the joint line because a too medial orientation would hit the thin aspect of the posterior glenoid and not provide a good bite for the screw. It has also been described that a medial and superior orientation could potentially damage the suprascapular nerve.[18] Surprisingly, in the arthro-EndoButton technique, the average angulation of the tunnel was 5.7°, whereas the guide is designed to provide a 10° angulation. This may highlight a certain degree of flexibility of the guide itself and/or variations in the positioning during the procedure. Nevertheless, the position of the tunnel in the arthro-EndoButton technique was the more reproducible compared with the 2 other techniques, thus advocating the use of such a guide.

In the axial plane, the average position of the bone graft was systematically statistically significantly different, more lateral, with both arthroscopic techniques. The arthro-screw and arthro-EndoButton techniques showed a slight average overhanging with respect to the joint line of 1.5 mm maximum. These results are consistent with those of Marion et al.[19] reporting an average overhanging of 1 mm at the 25% line and 2.2 mm at the 50% line with the arthro-screw technique. The open technique, considered the gold standard, allowed a mean position in the axial plane of approximately 1 mm medial to the joint line at the 2 levels of assessment to be obtained, in accordance with the gold-standard recommendation to avoid any overhanging with respect to the joint line because too lateral placement of the graft favors glenohumeral joint arthropathy.[4-7]

None of the 3 techniques was immune to too lateral or too medial positions of the graft, which was shown by the analysis of the dispersion of the values. With the arthro-screw technique, the position of the bone graft in the axial plane was statistically more variable compared with the open technique. With the same arthro-screw technique, Kany et al.[12] reported an average position between 5 mm medial and 3 mm lateral in 68% of shoulders, too medial (<5 mm) in 7%, and too lateral (>3 mm) in 24%. Boileau et al.[20] analyzed the results of another arthroscopic technique with screw fixation and reported a too medial position (<5 mm) in 3% of cases and too lateral (>5 mm) in 4%. The arthro-EndoButton technique had an equivalent variability compared with the open technique (no statistically significant difference). The systematic use of a specific intra-articular guide for tunnel drilling is likely to have influenced the reproducibility of the arthro-EndoButton technique in the axial plane, subsequently minimizing the risk of excessive medial or lateral placement of the graft.

In the sagittal plane, the open technique provided an average of 71% of the bone block inferior to the equator with low dispersion of the values. All techniques allowed an average position of at least half the length of the graft under the equator. This is in accordance with the recommendation of Patte et al.[21] to place the bone graft under the equator. Despite lack of a statistically significant difference, there was a trend toward having higher variability of the values with the arthroscopic techniques compared with the open technique. Furthermore, with the arthro-EndoButton technique, a smaller piece of the coracoid is harvested

Table 4. Position of Bone Block at Level of Line at 50% of Glenoid Height (Equator) in Axial Plane

	Open Latarjet (n = 79)	Arthro-screw (n = 87)	Arthro-EndoButton (n = 42)
Mean, mm	−0.9	+1.5	0
Range, mm	−5.7 to +4.7	−7.9 to +9.7	−3.7 to +3.5
95% CI, mm	−1.4 to +0.5	−0.9 to +2.1	−0.6 to +0.6

Arthro-EndoButton, arthroscopic Latarjet technique with EndoButton fixation; Arthro-screw, arthroscopic Latarjet technique with screw fixation; CI, confidence interval.

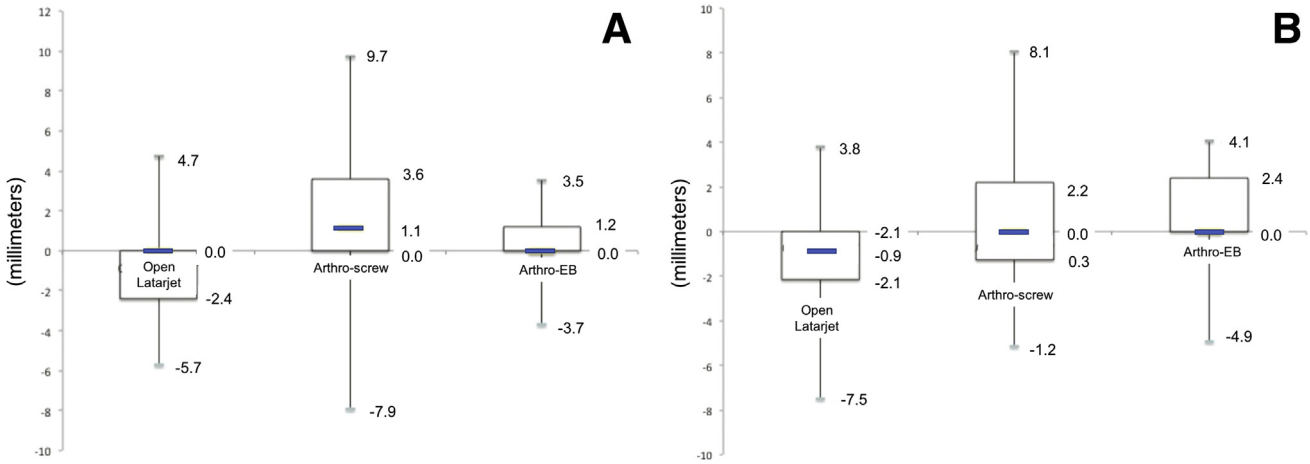

Fig 5. (A) Mean position and dispersion of values of bone block at level of 50% of glenoid height (equator). (B) Mean position and dispersion of values of bone block at level of 25% of glenoid height. The box plots display the median, quartiles, and minimum and maximum values of the distributions. Positive values are indicative of lateral placement whereas negative values are indicative of medial placement relative to the joint line. (Arthro-EB, arthroscopic Latarjet technique with EndoButton fixation; Arthro-screw, arthroscopic Latarjet technique with screw fixation.)

than with the 2 other techniques.[17] Subsequently, the higher values observed in this group could be explained by our method of assessment as a percentage of the graft under the equator.

Three studies recently reported the results of comparison between the arthro-screw technique and the open technique, with contrasting findings.[19,22,23] Whereas Zhu et al.[22] reported no overhanging positions in the axial plane and higher positions in the sagittal plane with the arthro-screw technique, Marion et al.[19] found lower and more lateral positions compared with the open technique. These discrepancies could be explained by several factors (sample size, protocol used for CT scan analysis, difference in execution of surgical technique) but could also be consistent with the overall higher variability of the positions compared with the open technique that we observed in our study.

Ideally, all surgical techniques should allow reproducible positioning of the graft and avoid extreme positions. In the Latarjet procedure, the bone graft is positioned on the glenoid through the subscapularis split, and this passage is one of the most difficult steps in the arthroscopic techniques. With the open technique, retractors are introduced to allow anterior glenoid exposure. The orientation of the drilling for screw insertion is then performed "freehand" under direct vision. Barth et al.[24] recently reported improvement in screw orientation using a specific guide for the open procedure. Under arthroscopic control, this step is difficult because of swelling of the subscapularis muscle. In the arthro-screw technique, the bone graft is stabilized with a specific handle and manipulated from anterior to posterior through the subscapularis split. The orientation of the drilling is then dependent on the orientation of the handle through the subscapularis, which can be challenging and involves a learning curve. In the arthro-EndoButton technique, the guide is used to drill the glenoid tunnel and the graft is pulled against the glenoid from the back. The guide provides an offset relative to the joint line in the axial plane but no landmark regarding the height. This could explain the highest reproducibility of the arthro-EndoButton technique observed in the axial plane but less reproducible positions in the sagittal plane. To facilitate this step, different tips have been described, such as elevation of the superior subscapularis with a rubber tube[22] and the use of specific subscapularis muscle spreaders[17] to increase the glenoid inferior neck exposure, thus potentially optimizing graft placement. The potential strength of our study is the number of cases available for analysis with a complete set of postoperative CT scans, analyzed with a standardized protocol.[11]

Limitations

We acknowledge this study presents some limitations. It is a multicenter study, and the number of surgeons using the same technique in the 3 subgroups was different. The procedures were performed by 2 surgeons in the open Latarjet group and by a single

Table 5. Position of Bone Block at Level of Line at 25% of Glenoid Height in Axial Plane

	Open Latarjet (n = 79)	Arthro-screw (n = 87)	Arthro-EndoButton (n = 42)
Mean, mm	−1.0	+0.3	+0.7
Range, mm	−7.5 to +3.8	−5.2 to +8.1	−4.9 to +4.1
95% CI, mm	−7.0 to +3.8	−0.2 to +0.9	−0.4 to +0.2

Arthro-EndoButton, arthroscopic Latarjet technique with EndoButton fixation; Arthro-screw, arthroscopic Latarjet technique with screw fixation; CI, confidence interval.

Table 6. Position of Bone Block in Sagittal Plane Relative to Equator

	Open Latarjet (n = 79)	Arthro-screw (n = 87)	Arthro-EndoButton (n = 42)
Mean, %	71	55	82
Range, %	34-100	0-100	10-100
95% CI, %	67.3-74	49-61	76-87

Arthro-EndoButton, arthroscopic Latarjet technique with EndoButton fixation; Arthro-screw, arthroscopic Latarjet technique with screw fixation; CI, confidence interval.

surgeon in the arthro-EndoButton group. On the other hand, 3 different surgeons performed the arthro-screw technique. The reproducibility of the measures was not studied among these 3 surgeons, and this potentially had an influence on the overall reproducibility of the technique compared with the 2 other techniques. Therefore, the differences observed in our results should be considered in light of this information. The lack of blinding of the surgeons according to the surgical technique is also a limitation. Transfer and selection bias may have influenced the results given that only 53.3% of the 390 patients undergoing Latarjet procedures had postoperative CT scans. In addition, the numbers of CT scans analyzed were different among the 3 subgroups, with the lowest number in the arthro-screw group. There are no validated data available in the literature that give the exact threshold beyond which the bone graft is considered too lateral. On the basis of clinical experience and radiographic analysis, it is nevertheless known that when overhanging occurs with respect to the joint line, there is a risk of increased secondary osteoarthritic changes after the Latarjet procedure.[5-7] We recommend any effort to avoid an overhanging position with either the open or arthroscopic technique. In the same way, a too medial position of the graft is potentially associated with failure of the procedure to stabilize the shoulder.[6,7] Our study cannot give these thresholds because no correlation with the end result of the procedure was performed regarding stability or arthritic changes of the joint. Therefore, the measurements of the position of the bone blocks in our study cannot be used as guidelines for surgical procedure performance.

Conclusions

This study shows that the position of the fixation devices and position of the bone graft with the arthroscopic techniques are statistically significantly different from those with the open technique with 2-dimensional CT assessment. In the sagittal plane, the arthro-screw technique provides the highest positions, and the arthro-EndoButton technique, the lowest. Overall, the mean position of the bone block with the open Latarjet technique in the axial plane is slightly medial to the joint line, as recommended. Conversely, with the arthroscopic techniques, the bone grafts are more lateral with a slight overhang. The main differences are observed in the dispersion of the values (more extreme positions) with the arthro-screw technique, given the acknowledged limitations. Despite the

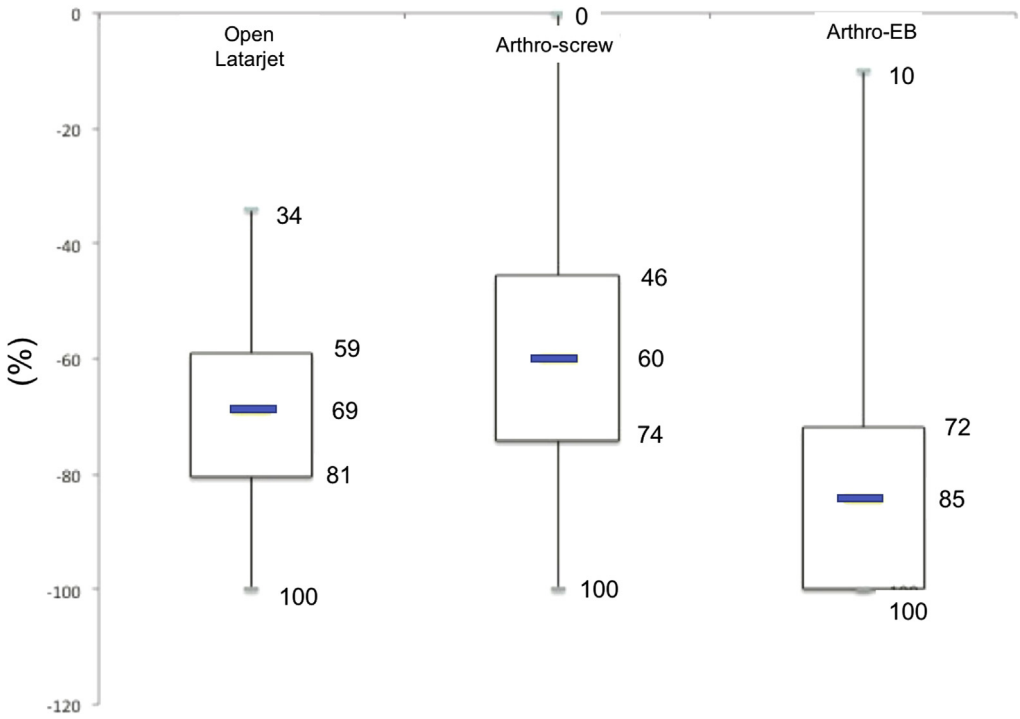

Fig 6. Mean values and dispersion of values of percentage of bone block inferior to equator (sagittal plane). The box plots display the median, quartiles, and minimum and maximum values of the distributions. Positive values are indicative of lateral placement whereas negative values are indicative of medial placement relative to the joint line. (Arthro-EB, arthroscopic Latarjet technique with EndoButton fixation; Arthro-screw, arthroscopic Latarjet technique with screw fixation.)

statistical significance, the clinical significance of these differences is yet unknown.

Acknowledgment

The authors thank the Société Francophone d'Arthroscopie. They also thank Pascal Garaud for performing the statistical analysis.

References

1. Latarjet M. A propos du traitement des luxation recidivantes de l'épaule. [Treatment of recurrent dislocations of the shoulder]. *Lyon Chir* 1954;49:994-997 [in French].
2. Latarjet M. Technique de la butée coracoidienne pré-glenoidienne dans le traitement des luxations récidivantes de l'épaule. *Lyon Chir* 1958;54:604-607 [in French].
3. Latarjet M. Techniques chirurgicales dans le traitement de la luxation récidivante de l'épaule (antéro-interne). *Lyon Chir* 1964;61:313-318 [in French].
4. Walch G. La luxation récidivante antérieure de l'épaule. *Rev Chir Orthop Reparatrice Appar Mot* 1991;77:177-191 (suppl 1) [in French].
5. Allain J, Goutallier D, Glorion C. Long-term results of the Latarjet procedure for the treatment of anterior instability of the shoulder. *J Bone Joint Surg Am* 1998;80:841-852.
6. Mizuno N, Denard PJ, Raiss P, Melis B, Walch G. Long-term results of the Latarjet procedure for anterior instability of the shoulder. *J Shoulder Elbow Surg* 2014;23:1691-1699.
7. Hovelius L, Sandstrom B, Olofsson A, Svensson O, Rahme H. The effect of capsular repair, bone block healing, and position on the results of the Bristow-Latarjet procedure (study III): Long-term follow-up in 319 shoulders. *J Shoulder Elbow Surg* 2012;21:647-660.
8. Lunn JV, Castellano-Rosa J, Walch G. Recurrent anterior dislocation after the Latarjet procedure: Outcome after revision using a modified Eden-Hybinette operation. *J Shoulder Elbow Surg* 2008;17:744-750.
9. Clavert P, Koch G, Neyton L, et al. Is anterior glenoid bone block position reliably assessed by standard radiography? A cadaver study. *Orthop Traumatol Surg Res* 2016;102:S281-S285.
10. Kraus TM, Graveleau N, Bohu Y, Pansard E, Klouche S, Hardy P. Coracoid graft positioning in the Latarjet procedure. *Knee Surg Sports Traumatol Arthrosc* 2016;24:496-501.
11. Barth J, Neyton L, Métais P, et al. Is the two-dimensional computed tomography scan analysis reliable for coracoid graft positioning in Latarjet procedures? *J Shoulder Elbow Surg* 2017;26:e237-e242.
12. Kany J, Flamand O, Grimberg J, et al. Arthroscopic Latarjet procedure: Is optimal positioning of the bone block and screws possible? A prospective computed tomography scan analysis. *J Shoulder Elbow Surg* 2016;25:69-77.
13. Lafosse L, Boyle S, Gutierrez-Aramberri M, Shah A, Meller R. Arthroscopic Latarjet procedure. *Orthop Clin North Am* 2010;41:393-405.
14. Molé D, Walch G. Traitement chirurgical des insatbilités de l'épaule. Articulation gléno-humérale. In: *Encyclopédie médico-chirurgicale. Techniques chirurgicales-orthopédie traumatologie*. Paris: Editions Techniques, 1993;44-265.
15. Lafosse L, Lejeune E, Bouchard A, Kakuda C, Gobezie R, Kochhar T. The arthroscopic Latarjet procedure for the treatment of anterior shoulder instability. *Arthroscopy* 2007;23:1242.e1-1242.e5.
16. Lafosse L, Boyle S. Arthroscopic Latarjet procedure. *J Shoulder Elbow Surg* 2010;19:2-12 (suppl).
17. Boileau P, Gendre P, Baba M, et al. A guided surgical approach and novel fixation method for arthroscopic Latarjet. *J Shoulder Elbow Surg* 2016;25:78-89.
18. Maquieira GJ, Gerber C, Schneeberger AG. Suprascapular nerve palsy after the Latarjet procedure. *J Shoulder Elbow Surg* 2007;16:e13-e15.
19. Marion B, Klouche S, Deranlot J, Bauer T, Nourissat G, Hardy P. A prospective comparative study of arthroscopic versus mini-open Latarjet procedure with a minimum 2-year follow-up. *Arthroscopy* 2017;33:269-277.
20. Boileau P, Thélu CÉ, Mercier N, et al. Arthroscopic Bristow-Latarjet combined with Bankart repair restores shoulder stability in patients with glenoid bone loss. *Clin Orthop Relat Res* 2014;472:2413-2424.
21. Patte D, Bancel P, Bernageau J. The vulnerable point of the glenoid rim. In: Bateman JE, Welsch RP, eds. *Surgery of the shoulder*. New York: Marcel Dekker, 1985;94-99.
22. Zhu Y, Jiang C, Song G. Arthroscopic versus open Latarjet in the treatment of recurrent anterior shoulder dislocation with marked glenoid bone loss. *Am J Sports Med* 2017;45:1645-1653.
23. Russo A, Grasso A, Arrighi A, Pistorio A, Molfetta L. Accuracy of coracoid bone graft placement: Open versus arthroscopic Latarjet. *Joints* 2017;5:85-88.
24. Barth J, Boutsiadis A, Neyton L, Lafosse L, Walch G. Can a drill guide improve the coracoid graft placement during the Latarjet procedure? A prospective comparative study with the freehand technique. *Orthop J Sports Med* 2017;5:2325967117734218.